



PRESENTING CLINICAL SIGNS

History: Grade 3/6 murmur. Vomits almost every day, has lost over 2 lb. Receiving metronidazole, Fortiflora, Cerenia.

DATE

12/14/21

ECHOCARDIOGRAPHIC FINDINGS

2D, M-mode, and Doppler study.

PERFORMED BY:

Shari Reffi, CVT

Left atrial size is normal. The mitral valve is normal. Left ventricular wall thickness is normal. Left ventricular internal dimensions are normal. Left ventricular systolic function is hyperdynamic. The aorta and aortic valve are normal. Right atrial and right ventricular dimensions are normal. The tricuspid valve is normal. The pulmonary artery and pulmonic valve are normal. No shunting lesions are visualized. No pericardial effusion or cardiac masses are seen.

INTERPRETED BY

Keith Blass, DVM,
MS, DACVIM
(Cardiology)

IVSd – 4.1 mm
LVPWd – 4.4 mm
LVIDd – 11.1 mm
LVIDs – 3.9 mm
FS – 64.8%
LVOT – 0.80 m/s
RVOT – 0.60 m/s

PATIENT

Felix Glynn

SPECIES

Feline

ASSESSMENT/RECOMMENDATIONS

Normal echocardiogram

This examination demonstrates no evidence of structural heart disease. While a definitive reason for Felix's murmur was not identified, it's likely that his murmur is functional/innocent in nature, as no flow abnormalities that could result in the development of a pathologic murmur were appreciated in the image set.

BREED

Bombay

No therapy is recommended based on this exam.

SEX

A recheck echocardiogram is recommended if the characteristics of Felix's murmur change, or if other new physical exam and/or clinical abnormalities suggestive of cardiac dysfunction develop.

MN

AGE

10 y

WEIGHT

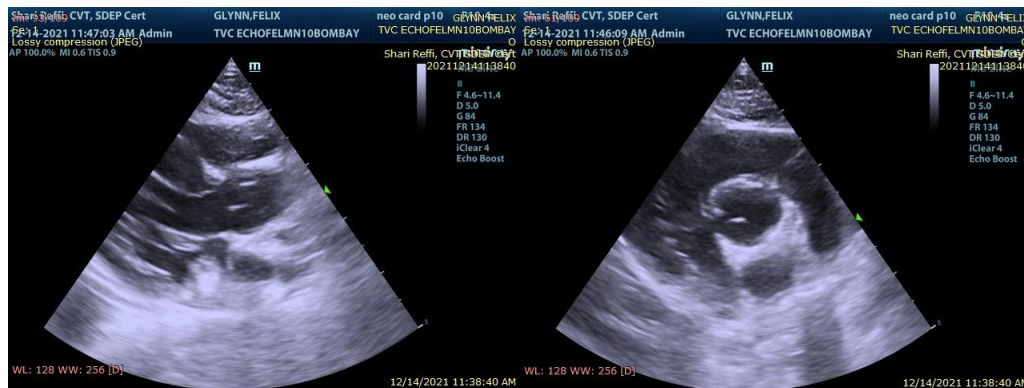
7.13 lb

HOSPITAL NAME

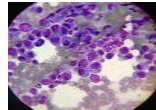
Tranquility VC

REFERRING VET

Dr. Antonelli



The information and recommendations provided are based on the images presented by the referring veterinarian. No evaluation can be communicated regarding pathology that was not



visible in the image/video clips provided.

DATE

12/14/21

Thank you for this referral. If the clinical or image interpretation does not parallel your findings or if I can be of any further assistance please contact me.

PERFORMED BY:

Keith Blass, DVM, MS, DACVIM (Cardiology)
KeithBlass@gmail.com
631-804-5754

Shari Reffi, CVT

INTERPRETED BY

Keith Blass, DVM,
MS, DACVIM
(Cardiology)

PATIENT

Felix Glynn

SPECIES

Feline

BREED

Bombay

SEX

MN

AGE

10 y

WEIGHT

7.13 lb

HOSPITAL NAME

Tranquility VC

REFERRING VET

Dr. Antonelli